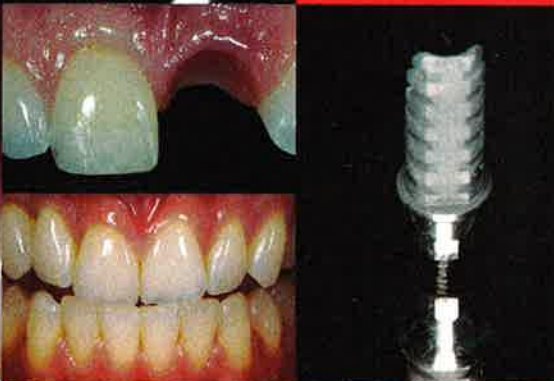
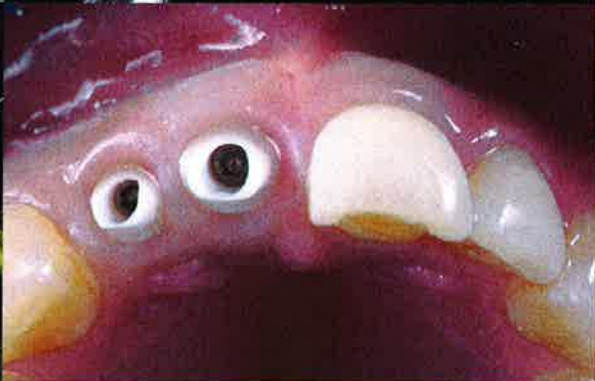
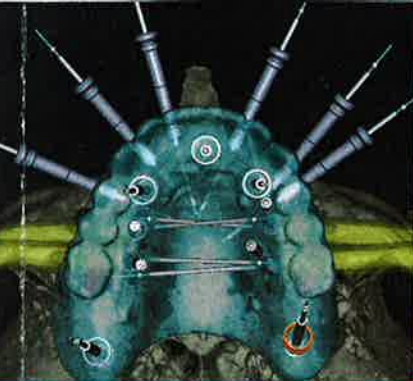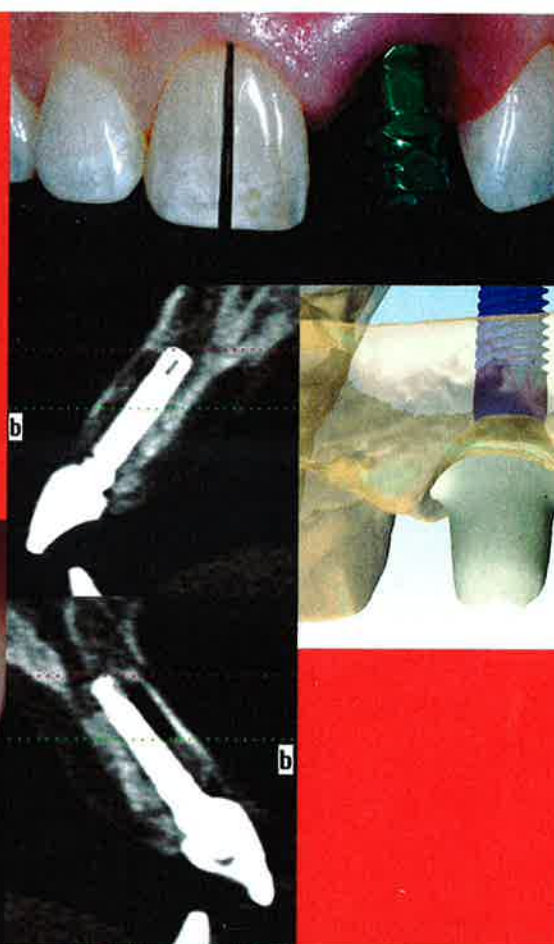
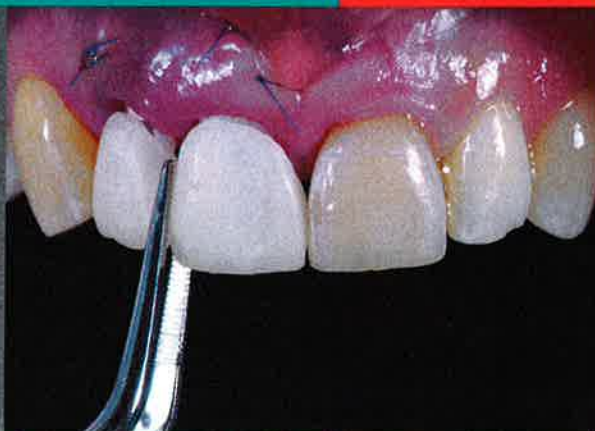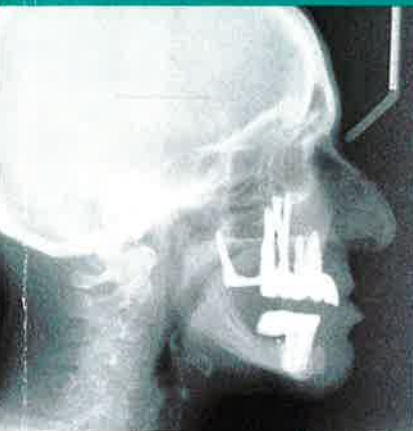


jcd

vol. 28 issue 2
Journal of Cosmetic Dentistry



Implants: Past, Present, and Future

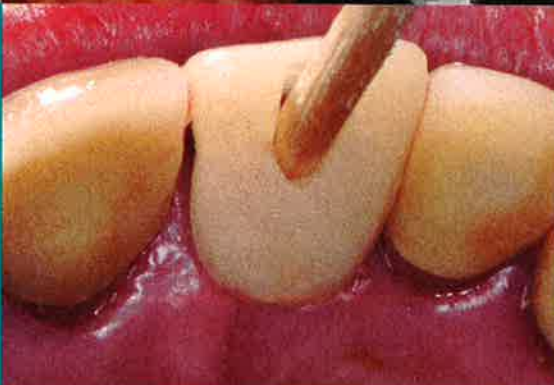Dr. Gerald Niznick

Flapless and Flap Implant Surgery

Drs. Michael A. Pikos and Marius Steigmann

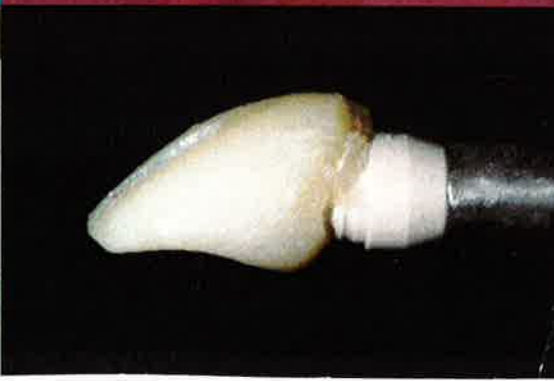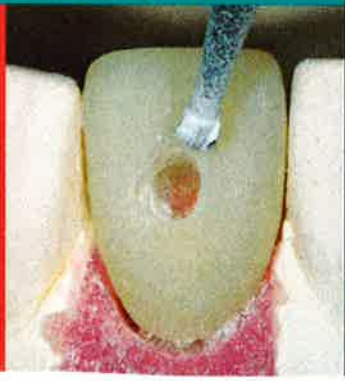A "No Bone" Solution—3 Hours Free CE

Mr. Stephen F. Balshi and Dr. Thomas J. Balshi



SUMMER 2012

AACD American Academy
of Cosmetic Dentistry®



A "NO BONE"

Treating the Atrophic Maxilla with an Immediate Implant-Supported Fixed Prosthesis

Stephen F. Balshi, MBE
Thomas J. Balshi, DDS, PhD, FACP



Learning Objectives:

After reading this article, the participant should be able to:

1. Identify patients who might be candidates for the protocol described.
2. Understand the indications for using zygoma and pterygomaxillary implants.
3. Recognize the minimally invasive and time-saving benefits of avoiding bone grafting (sinus lift and onlay) procedures.

SOLUTION

Abstract

Rehabilitation of the severely atrophic maxilla presents significant challenges for the restoring dental team. Inadequate bone volume often results in augmentation procedures that delay treatment and delivery of the final prosthetic solution. This article discusses the use of implant anchorage in extra-maxillary sites for the support of an immediately loaded screw-retained prosthesis.

A 71-year-old Caucasian female with an unremarkable medical history presented for treatment of her severely atrophic maxilla. She was treated with a combination of computer-guided standard-length implant placement as well as freehand zygomatic implant placement. A total of nine implants were placed to support an all-acrylic provisional prosthesis immediately after surgery. The final prosthesis was delivered five months after the initial implant placement.

The treatment plan, including implant placement and provisional prosthesis delivery, took less than four hours to complete under general anesthesia. The final prosthesis consists of a milled titanium framework that supports individual ceramic crowns, providing the patient with an excellent functional and esthetic result. The patient has been followed for four years since initial implant placement; there have been no postoperative complications to report.

The combination of the computer-guided and freehand implant placement to treat the atrophic maxilla provides the maxillary atrophied patient with an alternative to bone augmentation. This protocol provides the definitive solution for the patient in an expeditious yet predictable manner.

KEY WORDS: dental implant, osseointegration, atrophic maxilla, zygoma, pterygoid

Introduction

Originally described by Brånemark and colleagues,¹ prosthetic rehabilitation with dental implants and tissue-integrated prostheses has been a widely accepted treatment option for the edentulous arch. Patients who have been edentulous for many years or patients with extensive periodontal conditions may present a challenge to the practitioner for traditional implant placement due to limited bone quality and quantity. Several techniques have been used to successfully restore the atrophied maxilla by creating more bone volume. The techniques employed have included iliac block grafting procedures,² sinus augmentation,³ and Le Fort I osteotomies with interpositional bone grafting.⁴ In patients where bone atrophy and paranasal sinus pneumatization is less advanced, the use of tilted implants^{5,6} anterior and posterior to the maxillary sinus may provide predictable alternatives for the edentulous maxilla.

This article describes the rehabilitation of the severely atrophic maxillary arch using a combination of standard length endosseous implants in the anterior maxilla or in the pterygomaxillary region^{7,8} and longer implants placed in the zygomatic bone.⁹⁻¹² The implants were immediately loaded following the Teeth in a Day (PI Dental Center, Fort Washington, PA) protocol,^{13,14} using the conversion prosthesis technique^{15,16} of adapting an immediate removable denture to an all-acrylic resin screw-retained provisional prosthesis. This treatment, termed the No BoneZ Solution (PI Dental Center), uses remote implant anchorage to immediately rehabilitate the oral invalid to an all-acrylic resin screw-retained provisional prosthesis in a single surgical appointment. The total treatment time for patients

with this protocol typically is 12 to 18 weeks. This is routinely more efficient than grafting treatment options, which may be 12 to 18 months in duration. The cumulative survival rates of implants in the No BoneZ Solution protocol are higher than implants placed in grafted maxillae.¹⁷ And because there is no donor site in this protocol, there is no concern for donor site pain, trauma, swelling, or other forms of morbidity.

This article discusses a typical patient and her journey through the No BoneZ Solution protocol. The diagnosis and treatment planning are highlighted, along with the subsequent in-office visits until the delivery of the final prosthetic reconstruction.

Patient History

A 71-year-old Caucasian female presented to a private practice specializing in implant prosthodontics (Pi Dental Center). She was completely edentulous in both the maxillary and mandibular arches but had implant rehabilitation completed in the mandibular arch (Figs 1a & 1b). She presented with a maxillary removable complete denture and a screw-retained mandibular acrylic resin-to-metal prosthesis (Fig 2a). Both maxillary and mandibular prostheses had gold occlusal inlays on the bicuspids and molars (Figs 2b & 2c). The maxillary denture had a radiographic registration embedded in it by her previous dentist for the purpose of three-dimensional (3D) evaluation (Figs 1a & 1b). The patient stated she had been wearing a maxillary complete denture since she was 17 years old (54 years) and realized she had a significant amount of bone loss as a result. Her chief complaint was "constant jaw pain with ringing in the ears." She believed her jaw relationship "opened her up too

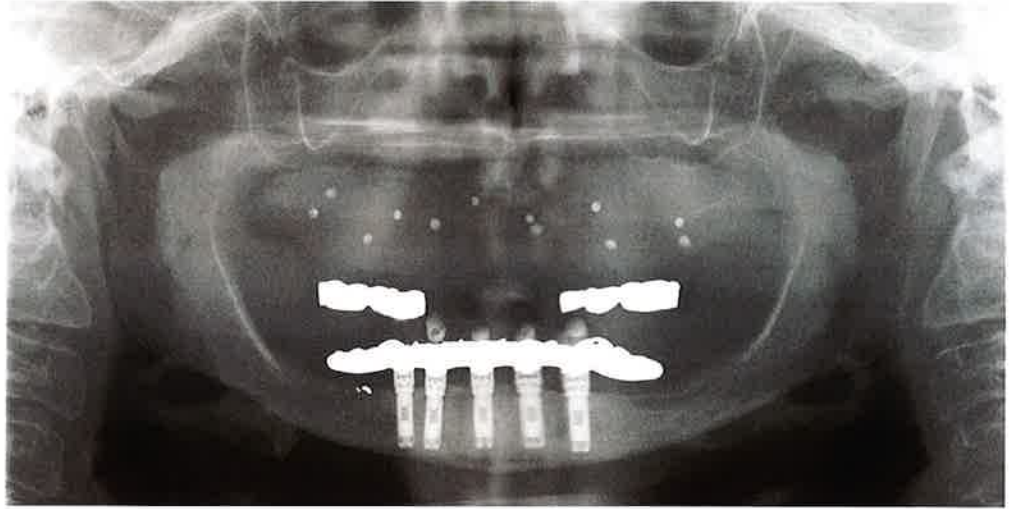


Figure 1a: Panoramic radiograph at initial presentation.

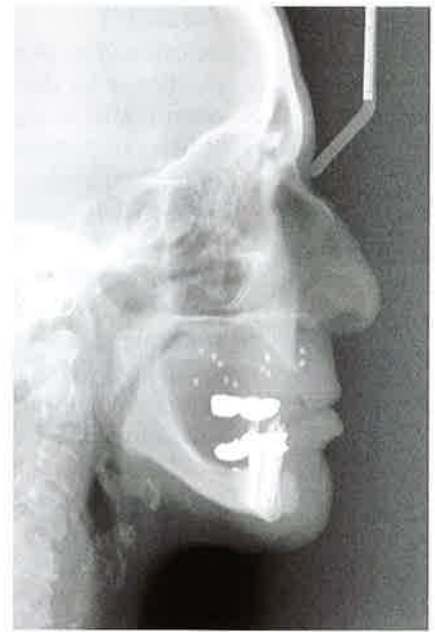


Figure 1b: Lateral cephalometric radiograph at initial presentation.

Patients who have been edentulous for many years or patients with extensive periodontal conditions may present a challenge to the practitioner for traditional implant placement due to limited bone quality and quantity.

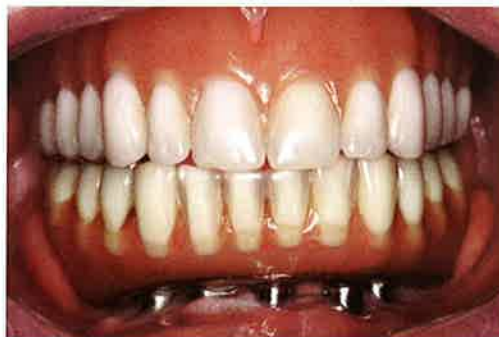

Figure 2a: Frontal view at initial presentation with maxillary complete denture and mandibular screw-retained acrylic-metal prosthesis.

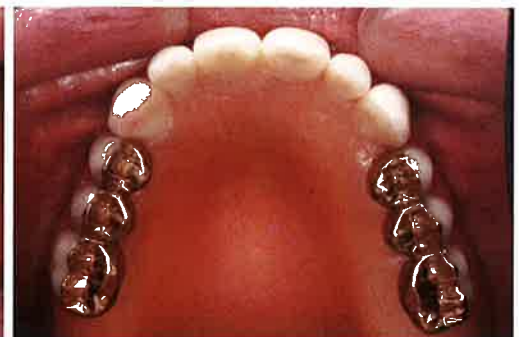

Figure 2b: Occlusal view of maxillary complete denture and mandibular screw-retained acrylic-metal prosthesis.

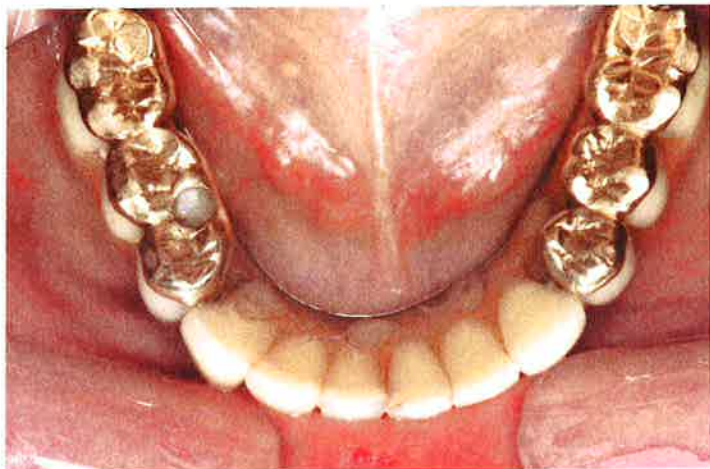

Figure 2c: Occlusal view of mandibular screw-retained acrylic-metal prosthesis at initial presentation.

much.” The patient reported good general health, suffering only from mitral valve prolapse, low blood pressure, and mild bouts of arthritis. She was previously prescribed 0.125 mg Synthroid, 100 mg Zoloft (for depression), and 400 mg Meprobamate (for jaw pain).

Treatment Plan

The traditional clinical and radiologic initial patient evaluation was performed. The lateral cephalometric radiograph (Fig 1b) revealed a “knife-edged” ridge in the maxilla. Advanced bone loss was also noted in the posterior maxilla (Fig 1a). A comprehensive treatment plan was presented to the patient that included the following:

- 1) A crestal incision in the maxillary arch with little mucosal reflection to reduce the alveolar ridge in the anterior maxilla, which would provide a more ideal platform for implant placement.
- 2) A reline of the current maxillary removable denture after the reduction of the alveolar ridge.
- 3) A cone-beam computed tomography (CBCT) scan, which would be used to virtually plan the implant placement.
- 4) Fabrication of a surgical template for standard-length implant placement.
- 5) Fabrication of an all-acrylic resin provisional prosthesis based on the virtual implant placement.
- 6) Surgical placement of five standard-length Brånemark System implants (three in the anterior maxilla and one in each pterygomaxillary region bilaterally) and four zygomatic implants (two each side bilaterally).
- 7) Connection of the prefabricated all-acrylic resin provisional prosthesis to the nine implants.
- 8) Delivery of the final prosthesis approximately 20 weeks after implant placement.

The patient agreed to this comprehensive treatment plan.

Treatment

Preoperative Clinical Procedure

The authors believe that all dental implant treatment must be prosthetically driven. In other words, the first step in the process is to determine (with the patient’s agreement) the final prosthetic solution. It was explained to the patient that the ideal final prosthesis for the maxilla would be a milled titanium framework constructed to support individual porcelain crowns, and a customized gingival veneer to compensate for the lost vertical dimension that had resulted from 54 years of denture wearing. To complement this ideal final prosthetic solution in the maxilla, it was suggested to the patient that a new mandibular definitive reconstruction be fabricated that consisted of a milled titanium framework supporting acrylic resin denture teeth and the same customized gingival veneer. In addition to material preferences, a new mandibular prosthesis would allow an Angle’s Class I occlusal relationship to be established.

A small crestal incision was made and the appropriate amount of alveoplasty was performed in the maxillary arch to establish a bone platform for implant placement and the spatial requirements for the definitive prosthesis. The flaps were sutured and a chair-side hard reline was completed. A polyvinyl siloxane centric occlusal index was taken to record this relationship for the laboratory and also to stabilize the prostheses during the forthcoming CBCT scanning procedures. An open-tray abutment level impression was taken in the mandibular arch and the resulting mandibular master cast was articulated using the existing mandibular prosthesis opposing a model of the maxillary removable denture. Additionally, a stone model of the existing mandibular screw-retained prosthesis was cross-articulated.

The specific guided surgery protocol that would be employed (NobelClinician; Nobel Biocare; Yorba Linda, CA) requires a dual CT scan technique.¹⁸⁻²⁰ The first scan is of the patient with the removable prosthesis, which contains the radiographic registration. The second scan is of the removable prosthesis alone. The digital imaging and communications in medicine (DICOM) files were exported to the diagnostic and virtual treatment-planning software (NobelClinician). The 3D virtual working environment allows the clinician and the laboratory to collaborate on the ideal placement of the implants with consideration to biomechanics, prosthesis design, and esthetics.

The maxillary virtual implant planning was designed with three external connection implants (NobelSpeedy Groovy; Nobel Biocare) in the anterior

region, one external connection implant in each pterygomaxillary region bilaterally, and two zygomatic implants (Brånemark System Zygoma, Nobel Biocare) on each side bilaterally (Figs 3a-3d).

The computer-assisted design (CAD) files of the maxillary virtual planning were transmitted through the Internet to the production facility (NobelProcera; Mahwah, NJ), where those files dictated stereoliththic construction of the surgical template. At the same time, a stereoliththic copy of the patient's maxillary removable complete denture was fabricated to assist the laboratory in fabrication of the screw-retained prostheses.

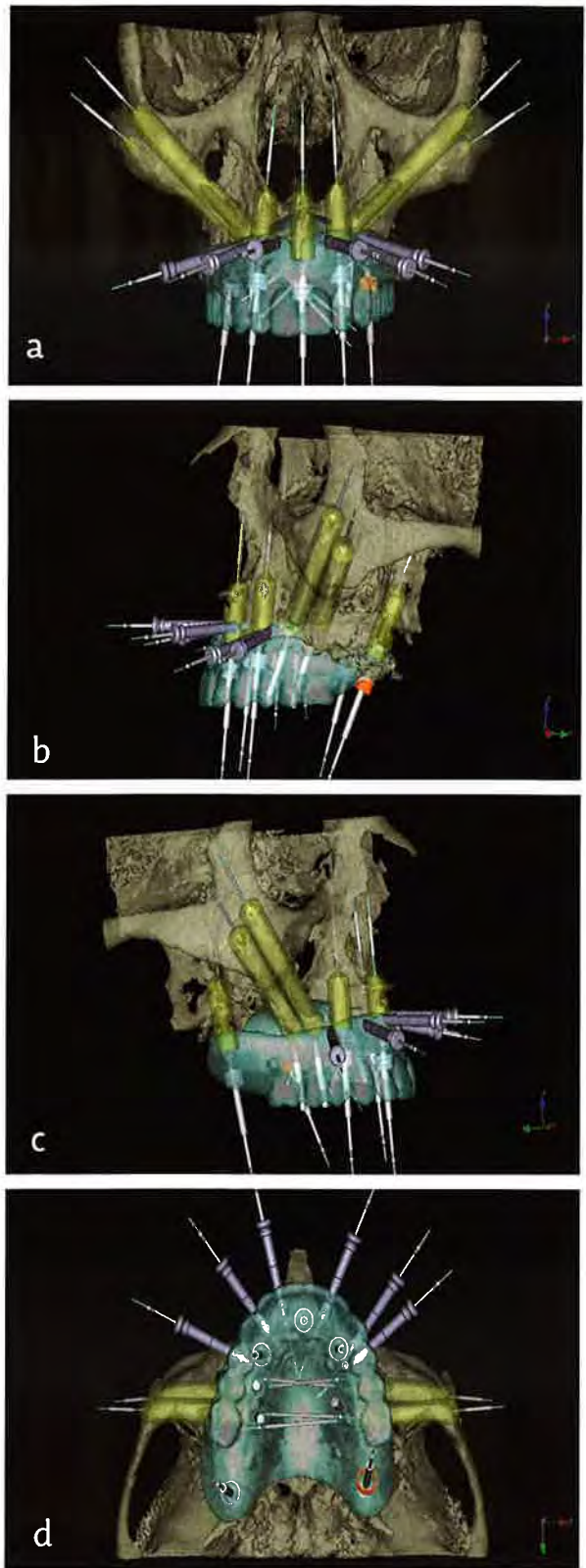
Preoperative Laboratory Procedures

Following this specific guided surgery protocol,¹⁸⁻²⁰ the laboratory retro-engineered an implant-level master cast with a soft tissue replication. Because of thread timing issues associated with the zygomatic implants, those replicas were not incorporated into the master cast. Using the centric occlusal index taken before the CBCT scan, the maxillary master cast could be articulated with the stereoliththic duplicate of the patient's denture against the previously articulated stone model of the existing mandibular prosthesis. Appropriate transmucosal abutments were installed onto the maxillary master cast (Fig 4) on which the all-acrylic resin screw-retained provisional prosthesis could be fabricated. Since there were only replicas present in the model for the standard length implants, just five prosthetic cylinders could be processed into the acrylic in the laboratory. The remaining four prosthetic cylinders for the zygomatic implants would be connected intra-orally during the surgical procedure immediately after implant placement.

Since the mandibular abutment level master cast was cross articulated, it was possible for the laboratory to fabricate the aforementioned new mandibular acrylic-to-titanium prosthesis at the same time as the maxillary all-acrylic resin prosthesis (Figs 5a-5c). Additionally, the laboratory could provide the clinician with a surgical index. This index would reference the maxillary surgical template to the newly fabricated definitive mandibular prosthesis (Fig 6) and would stabilize the surgical template in the patient during the clinical procedures.

Implant Placement and Prosthesis Delivery

It is the authors' preference to administer general anesthesia with nasal intubation to patients undergoing zygomatic implant placement. The surgical template was carefully delivered to the patient with the surgical index. Using the specific guided surgery drilling system, the five standard-length external connection implants were placed in a flapless manner. Once those implants were placed, the surgical template was removed and the tissue reflection commenced for placement of the zygomatic implants. These implants range from 30 to 52.5 mm in length, have a rounded apex, and a 45° bend at the coronal aspect to correct the prosthetic access for the palatally inclined implant (Fig 7). The implants have dual anchorage at the remainder of the max-



Figures 3a-3d: Screen capture from NobelClinician software of the completed virtual planning from (a) a frontal view, (b) a left lateral view, (c) a right lateral view, (d) an occlusal view.

The 3D virtual working environment allows the clinician and the laboratory to collaborate on the ideal placement of the implants with consideration to biomechanics, prosthesis design, and esthetics.

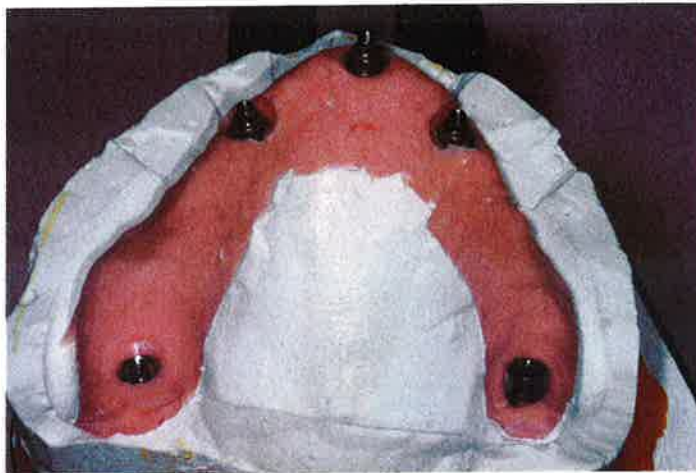

Figure 4: Retro-engineered implant-level master cast from the surgical template. The master cast has transmucosal abutments placed on the implant replicas, bringing the prosthetic platform to a more desirable relationship with the soft tissue.

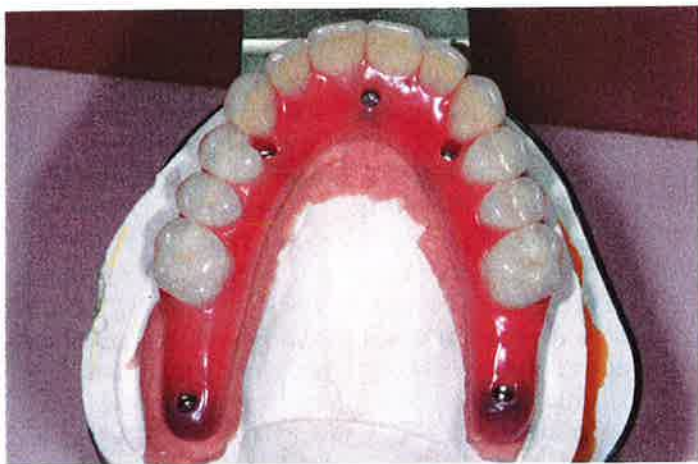

Figure 5a: Occlusal view of the prefabricated all-acrylic resin provisional prosthesis connected to the standard-length Brånemark System implants.

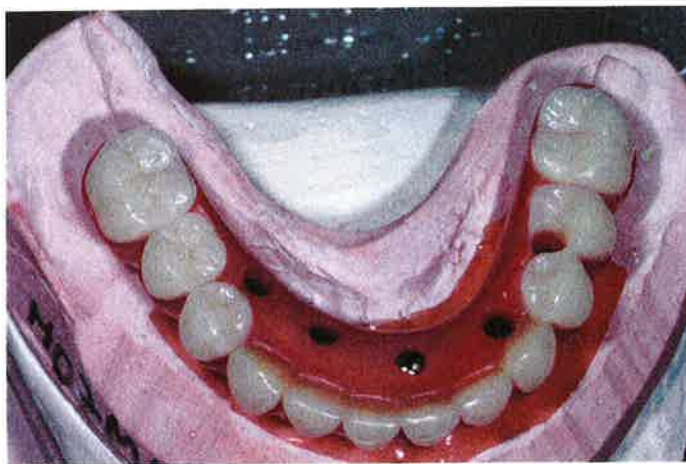


Figure 5b: Occusal view of the new definitive mandibular screw-retained prosthesis. A milled titanium framework supports the acrylic resin denture teeth.

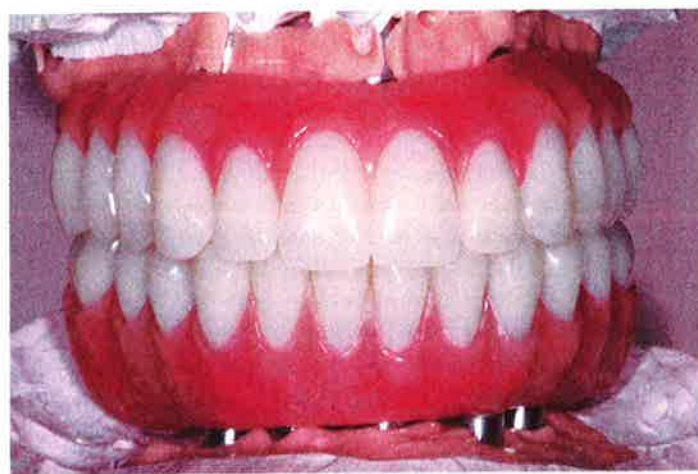

Figure 5c: Frontal view of the prefabricated maxillary provisional prosthesis and mandibular definitive prosthesis.

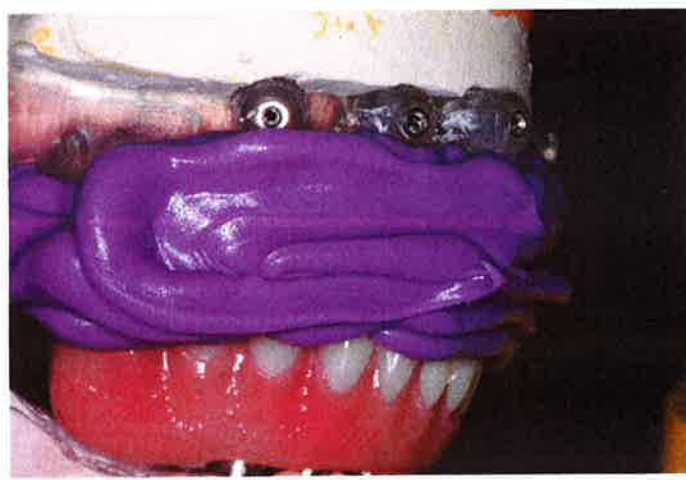


Figure 6: Right lateral view of the surgical index. This index will be used to position the surgical template in the patient with relation to the new mandibular definitive prosthesis.



Figure 7: The Brånemark System Zygoma Implant: (a) regular platform external hex connection, (b) prosthetic access is at a 45° angulation from the long axis of the implant, (c) the implant body consists of two diameters [4.6 mm at the coronal or maxillary end; 3.9 mm at the apical or zygomatic end], (d) the apex is a rounded tip to prevent sharp edges when the implant penetrates the lateral wall of the zygoma.

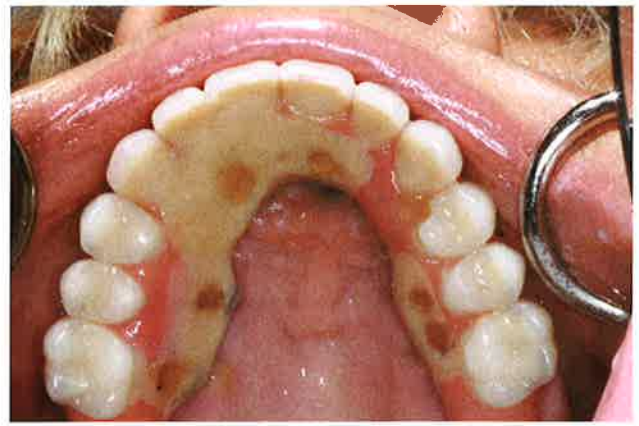

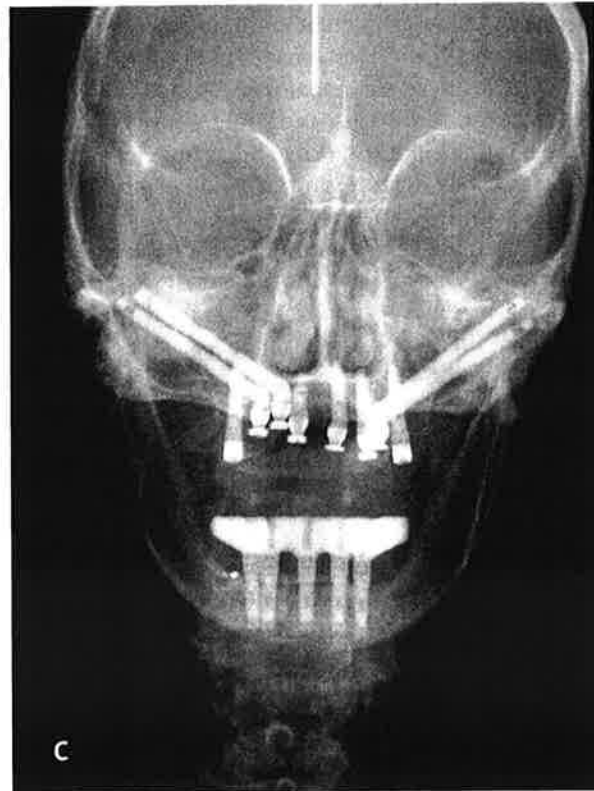
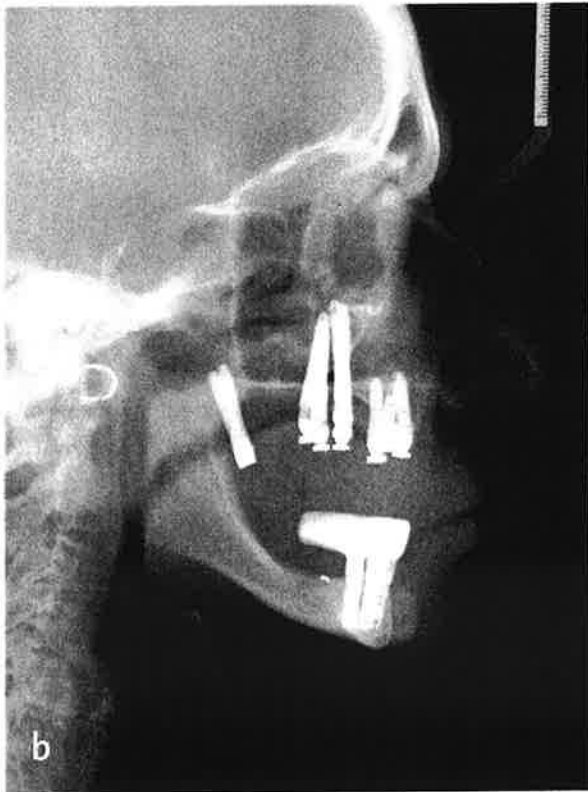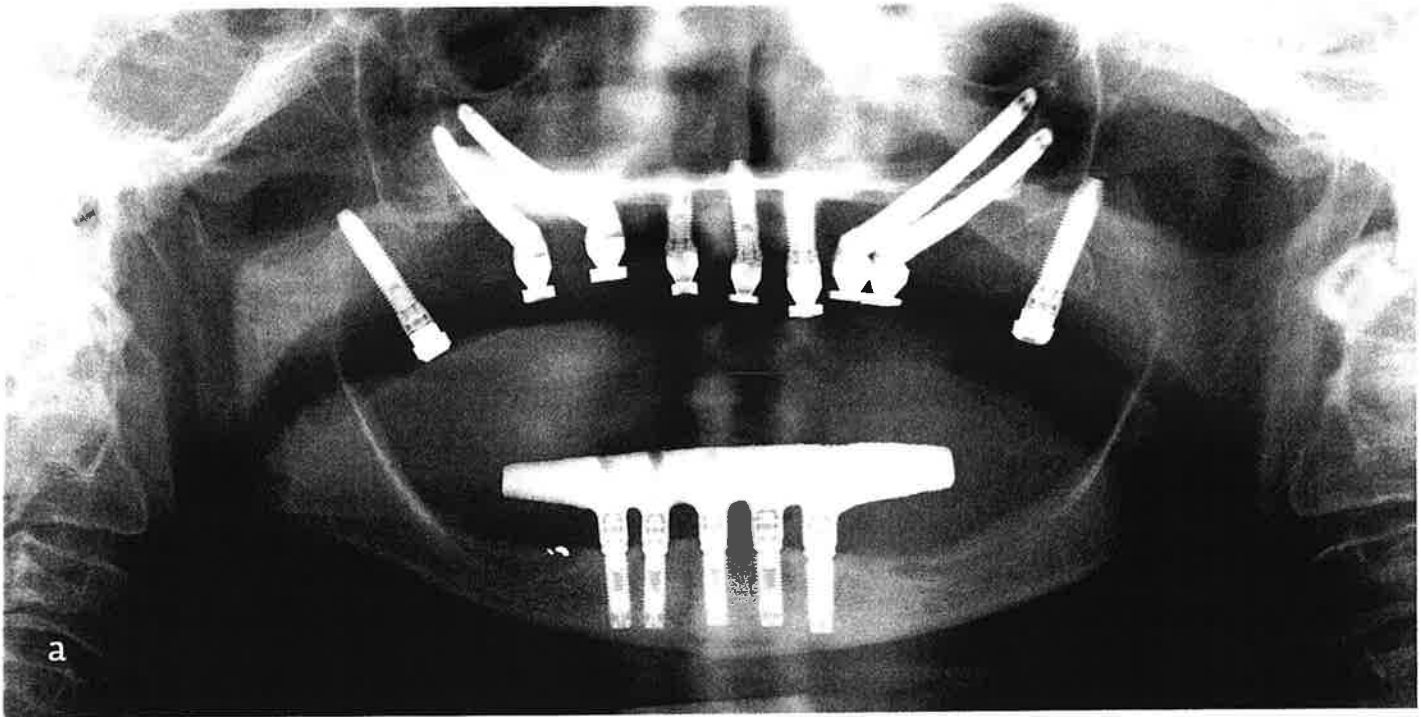
Figure 8: Occlusal view of the maxillary all-acrylic resin provisional prosthesis connected to all nine implants (five standard length, four zygomatic).

illa and at the zygoma, oftentimes transecting the maxillary sinus. When the implants were at their desired depth and orientation, the implant mounts were removed and the appropriate transmucosal abutments were connected. Following the Teeth in a Day protocol as described in the literature,¹²⁻¹⁴ the maxillary all-acrylic resin provisional prosthesis was modified to pick up the position of the temporary prosthetic cylinders for the zygomatic implants (Fig 8). Any occlusal adjustments were made and the access holes were filled with a firmly packed gauze strip or Teflon tape, followed by a light-cured provisional resin (Fermit LC, Ivoclar Vivadent; Amherst, NY). The patient was then extubated and allowed to recover from the general anesthetic. Postoperative panoramic, lateral, and anteroposterior cephalometric radiographs were made (Figs 9a-9c). The patient was asked to return to the office the next day for a healing check and to discuss all pertinent postoperative instructions. After 12 weeks or more of healing, she would present to initiate the construction of the maxillary definitive prosthesis.

Prosthetic Procedures

The patient returned 13 weeks after implant placement for final impression of the maxillary arch. Following the Teeth in a Day protocol,¹²⁻¹⁴ the provisional prosthesis was used as an impression splint to obtain a verified master cast. After the master cast was fabricated, the provisional prosthesis was used to articulate the master cast against a model of the mandibular definitive restoration.

The articulated models were sent to the laboratory for the fabrication of the definitive prosthesis. The patient elected to proceed with the authors' recommendation and receive the prosthesis that was built with individual porcelain crowns, all of which were supported by an underlying robotically milled titanium framework. A resin pattern designed from an approved tooth setup



Figures 9a-9c: Postoperative radiographs with maxillary provisional and mandibular definitive prostheses delivered: (a) panoramic, (b) lateral cephalometric, (c) anteroposterior cephalometric.

(Fig 10) was constructed in the laboratory; it would be copy-milled in titanium. The framework was opaqued and individual all-porcelain crowns were fabricated on each titanium preparation. Once the crowns were cemented onto the titanium framework, the appropriate customized gingival resin veneer was applied and the completed prosthesis (Fig 11) was returned to the prosthodontist. The patient presented eight weeks after final impression for delivery of the maxillary definitive prosthesis (Fig 12). A maxillary occlusal guard was also fabricated for use at night. Post-delivery panoramic, lateral, and anteroposterior cephalometric radiographs were made (Figs 13a-13c). The patient was instructed to have professional hygiene on a three-month recall until further notice. The patient has had unremarkable follow-up for four years.

Discussion

The No BoneZ Solution protocol provides comprehensive patient care for the fixed reconstruction of the severely atrophic maxilla in the fewest number of clinical sessions. Using the patient example described above, the following clinical sessions should be noted:

- **Session 1.** Diagnosis, treatment planning, consultation, jaw relationships recorded; minor alveoplasty to eliminate the knife edge ridge, hard relines of maxillary denture, and CBCT dual scan for virtual planning.
- **Session 2.** Implant surgery and delivery of a fixed screw-retained, all-acrylic provisional prosthesis.
- **Session 3.** Thirteen weeks after implant placement surgery, final impressions and occlusal records are complete and the laboratory prosthesis construction is initiated.
- **Session 4.** Delivery of the final definitive prostheses with an occlusal guard.

Comprehensive prosthodontic rehabilitation can be accomplished in as few as these four clinical treatment sessions. This treatment protocol is highly dependent on the accuracy of the prosthetically driven virtual plan, the precision of the laboratory procedures prior to implant surgery, and the ability to combine computer-guided implant surgery and full-flap zygomatic implant surgery in one session, which includes the connection of the zygomatic implants to the previously constructed screw-retained provisional prosthesis.

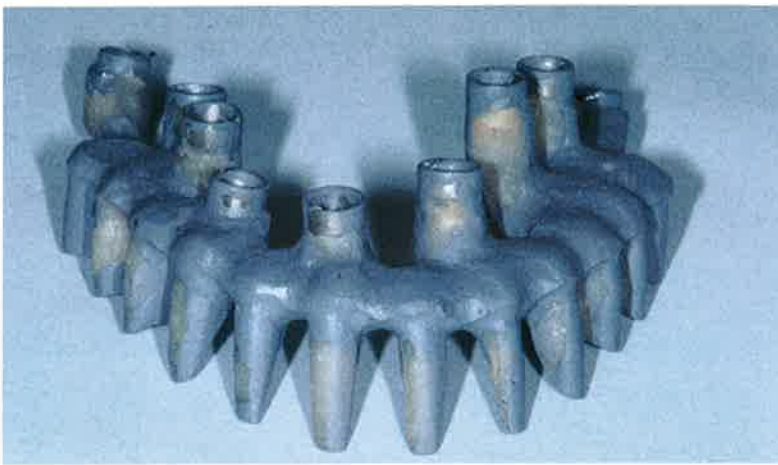

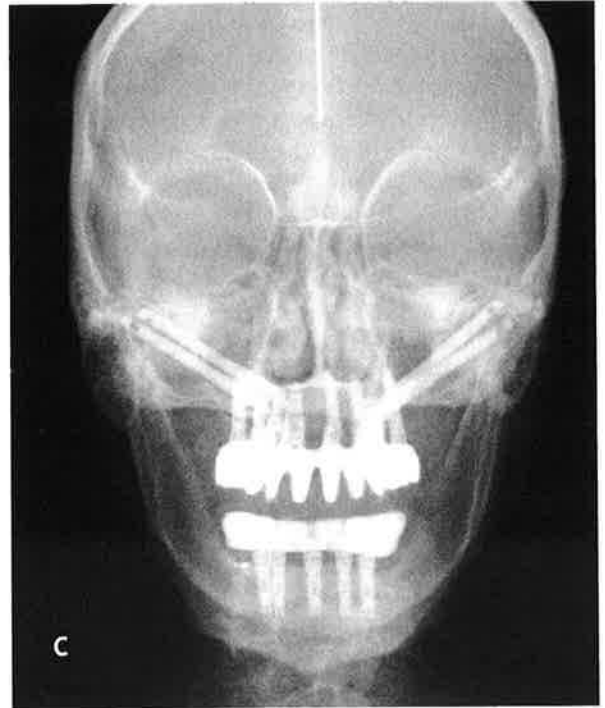
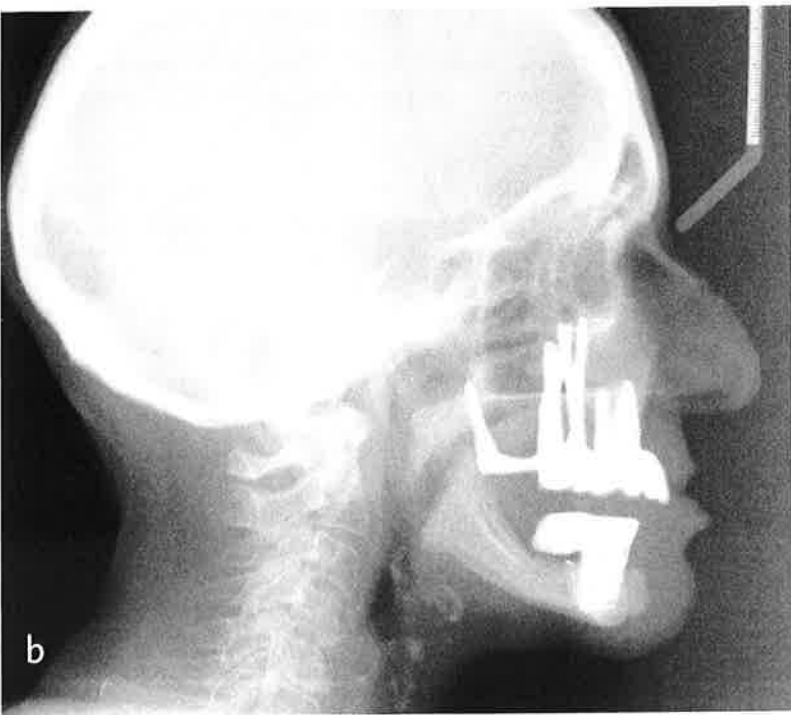
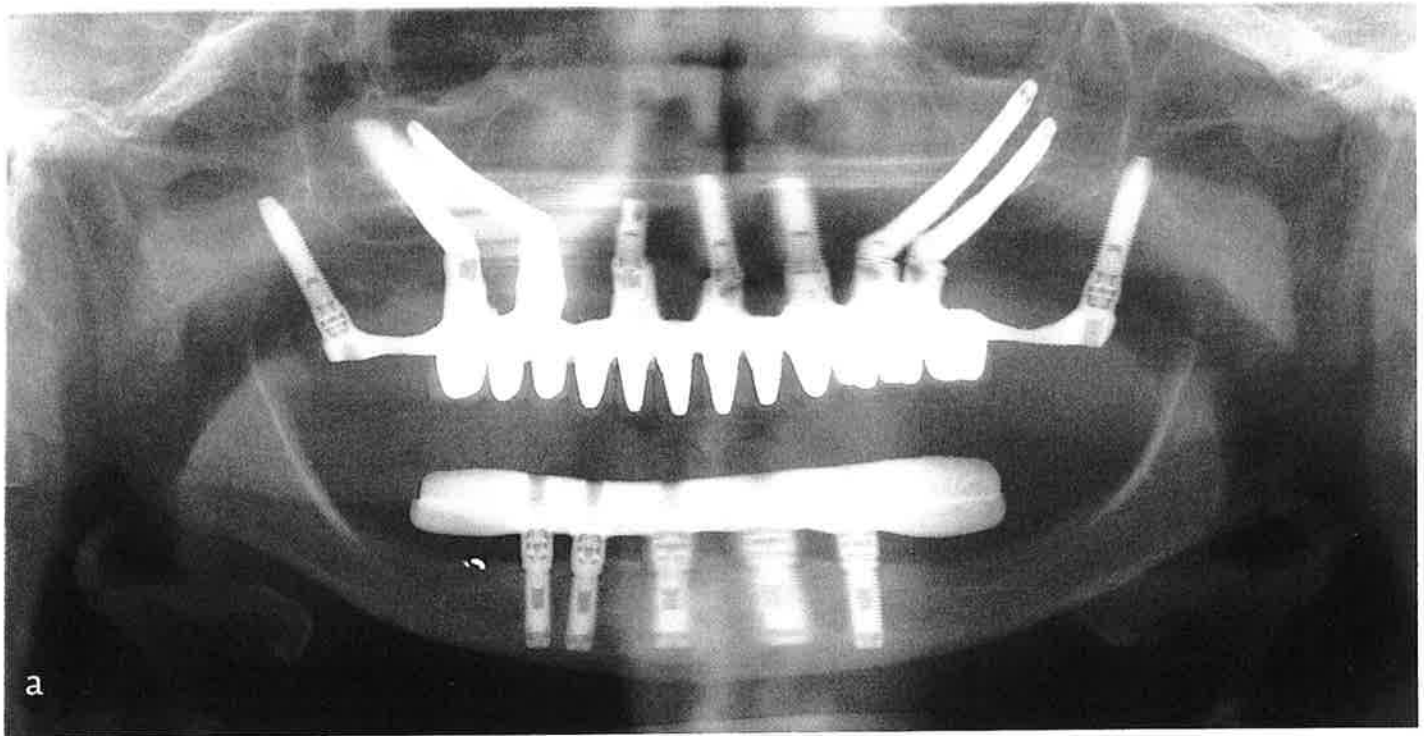
Figure 10: Resin pattern for maxillary definitive prosthesis designed to support individual ceramic crowns.

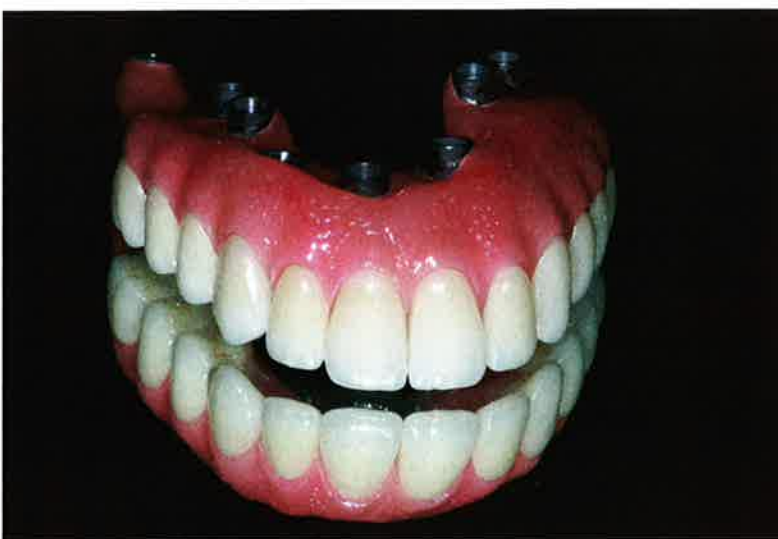

Figure 11: Completed maxillary definitive prosthesis consisting of a milled titanium framework supporting individual zirconia crowns and a customized gingival veneer.

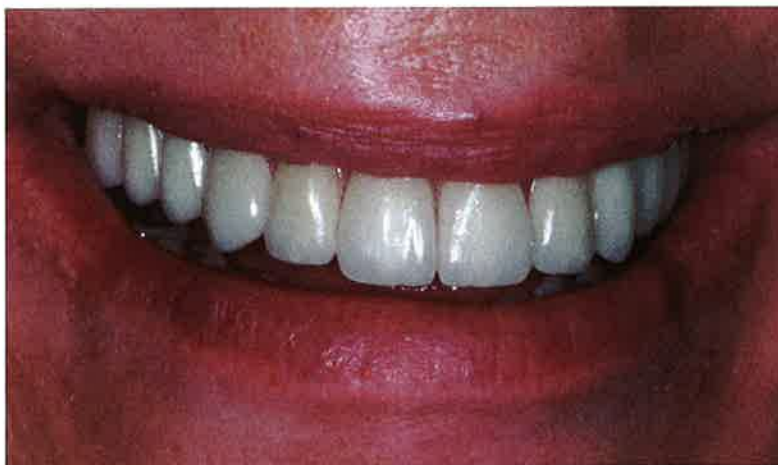

Figure 12: Frontal view following delivery of definitive maxillary prosthesis.



Figures 13a-13c: Postoperative radiographs with maxillary and mandibular definitive prostheses delivered: (a) panoramic, (b) lateral cephalometric, (c) anteroposterior cephalometric.

To achieve optimal esthetics for the severely atrophic maxillary rehabilitation, one must take into account aspects of restoring the lower third of the face. The principles of facial and lip support used in complete denture fabrication appropriately apply to this protocol. Prior to initiating surgical implant placement, the clinician needs to study facial form and select denture teeth of the appropriate mold and size that complement the patient's facial features. Although the current societal trend leans heavily toward the "whiter and brighter" smile, the atrophic maxilla patient may be better cosmetically restored with more natural shade selection. Choosing a variety of shades for the anterior and bicuspid teeth creates a color palate that works in harmony with nature.

Because the No BoneZ Solution protocol uses a fixed implant-supported provisional prosthesis, there is a three-month healing period during which both clinician and patient can evaluate the overall facial and dental esthetics before construction of the final prosthesis is initiated. When the dental esthetics are approved in the provisional prosthesis, replication of the dental anatomy can be captured digitally and reproduced in a variety of ceramic materials.

The accuracy of the impression procedure emanating from the Teeth in a Day protocol permits the total construction of the final prosthesis as described above without the need for try-in visits. Additionally, the No BoneZ Solution protocol is much less invasive than sinus elevation, bone grafting, or inlay or onlay bone grafting usually using the iliac crest as the donor site. When bone grafting to the maxilla is used, there is a delay in the treatment until the graft has stabilized and is mature enough for implant placement. This often requires the patient to function without a maxillary denture, so as not to put occlusal loading pressure on the healing bone graft.

Summary

The No BoneZ Solution protocol provides a restorative option for patients with severely atrophic maxillary bone. This protocol does not require bone augmentation and significantly reduces total treatment time for the patient compared to alternative procedures.

Acknowledgments

The authors thank Dr. Glenn Wolfinger and the staff of the Pi Dental Center (Fort Washington, PA) for their kind and gentle treatment of this patient; Mr. Dan Delaney and Dr. Brian Wilson for general anesthesia support; and Dr. Chantal Malevez and Prof. Per-Ingvar Brånemark for guidance and inspiration.

References

1. Brånemark P-I, Adell R, Breine U, Hansson B, Lindstrom J, Ohlsson A. Intraosseous anchorage of dental prostheses. part 1: experimental studies. *Scand J Plast Reconstr Surg.* 1969;3(2):81-100.
2. Isaksson S, Alberius P. Maxillary alveolar ridge augmentation with onlay bone-grafts and immediate endosseous implants. *J Craniomaxillofac Surg.* 1992 Jan;20(1):2-7.
3. Wood R, Moore D. Grafting of the maxillary sinus with intraorally harvested autogenous bone prior to implant placement. *Int J Oral Maxillofac Implants.* 1988 Fall;3(3):209-14.
4. Isaksson S, Ekfeldt A, Alberius P, Blomqvist J. Early results from reconstruction of severely atrophic (Class IV) maxillas by immediate endosseous implants in conjunction with bone grafting and Le Fort I osteotomy. *J Oral Maxillofac Surg.* 1993 Jun;22(3):144-8.
5. Krekmanov L, Kahn M, Rangert B, Lindström H. Tilting of posterior mandibular and maxillary implants for improved prosthesis support. *Int J Oral Maxillofac Implants.* 2000 May-Jun;15(3):405-14.
6. Aparício C, Perales P, Rangert B. Tilted implants as an alternative to maxillary sinus grafting: a clinical, radiologic, and Periotest study. *Clin Implant Dent Relat Res.* 2001;3(1):39-49.
7. Tulasne J. Implant treatment of missing posterior dentition. In: Albrektsson T, Zarb G, editors. *The Brånemark osseointegrated implant.* Hanover Park (IL); Quintessence Pub.; 1989. p. 103-16.
8. Krogh P. Anatomic and surgical considerations in the use of osseointegrated implants in the posterior maxilla. *Oral Maxillofac Surg Clin North Am.* 1991;3:853-69.
9. Parel S, Brånemark P-I, Ohrenell L, Svensson B. Remote implants anchorage for the rehabilitation of maxillary defects. *J Prosthet Dent.* 2001 Oct;86(4):377-81.
10. Bedrossian E, Stumpel L III, Beckley M, Indresano T. The zygomatic implant: preliminary data on treatment of severely resorbed maxillae. *Int J Oral Maxillofac Implants.* 2002 Nov-Dec;17(6):861-65.
11. Malevez C, Abarca M, Durdu F, Daelemans P. Clinical outcome of 103 consecutive zygomatic implants: a 60 to 48-months follow-up study. *Clin Oral Implants Res.* 2004 Feb;15(1):18-22.
12. Balshi SF, Wolfinger GJ, Balshi TJ. A retrospective analysis of 110 zygomatic implants in a single-stage immediate loading protocol. *Int J Oral Maxillofac Implants.* 2009 Mar-Apr;24(2):335-41.

13. Balshi TJ, Wolfinger GJ. Teeth in a Day for the maxilla and mandible: case report. *Clin Implant Dent Relat Res.* 2003;5(1):11-6.
14. Balshi SF, Wolfinger GJ, Balshi TJ. A prospective study of immediate functional loading following the Teeth in a Day protocol: a case series of 55 edentulous maxillas. *Clin Implant Dent Relat Res.* 2005;7(1):24-31.
15. Balshi TJ. The biotes conversion prosthesis: a provisional fixed prosthesis supported by osseointegrated titanium implants for restoration of the edentulous jaw. *Quintessence Int.* 1985 Oct;16(10):667-77.
16. Balshi TJ, Wolfinger GJ. Conversion prosthesis: a transitional fixed implant-supported prosthesis for an edentulous arch—a technical note. *Int J Oral Maxillofac Implants.* 1996 Jan-Feb;11(1):106-11.
17. Keller E, Tolman D, Eckert S. Surgical-prosthetic reconstruction of advanced maxillary bone compromise with autogenous onlay block grafts and osseointegrated implants: a 12-year study of 32 consecutive patients. *Int J Oral Maxillofac Implants.* 1999 Mar-Apr;14(2):197-209.
18. Van Steenberghe D, Naert I, Andersson M, Brajnovic J, Van Cleynenbreugel J, Suetens P. A custom template and definitive prosthesis allowing immediate implant loading in the maxilla. *Int J Oral Maxillofac Implants.* 2002 Sep-Oct;17(5):663-70.
19. Parel SM, Triplett RC. Interactive imaging for implant planning, placement, and the prosthesis construction. *J Oral Maxillofac Surg.* 2004 Sep;62(9 Suppl 2):41-7.
20. Balshi SF, Wolfinger GJ, Balshi TJ. Surgical planning and prosthesis construction using computed tomography, CAD/CAM technology, and the internet for immediate loading of dental implants. *J Esthet Restor Dent.* 2006;18(6):312-23; discussion 324-5. **jCD**

This treatment protocol is highly dependent on the accuracy of the prosthetically driven virtual plan, the precision of the laboratory procedures prior to implant surgery, and the ability to combine computer-guided implant surgery and full-flap zygomatic implant surgery in one session.



Mr. Stephen F. Balshi is a biomedical engineer and president of CM Prosthetics dental laboratory. He is the director of research for PI Dental Center at the Institute for Facial Esthetics, in Fort Washington, Pennsylvania. He can be contacted at stephen.balshi@cmprosthetics.com.



Dr. Thomas J. Balshi is a clinical professor at Temple University and an adjunct professor at Nova Southeastern University. A board-certified prosthodontist, he is the founder of PI Dental Center at the Institute for Facial Esthetics, in Fort Washington, Pennsylvania. He can be contacted at Thomas.Balshi@pidentalcenter.com.

Disclosure: The authors have financial arrangements with PI Dental Center and Nobel Biocare. Dr. Balshi developed the Teeth in a Day Protocol and the No BoneZ Solution.

AACD Self-Instruction Continuing Education Information



General Information

This continuing education (CE) self-instruction program has been developed by the American Academy of Cosmetic Dentistry (AACD) and an advisory committee of the *Journal of Cosmetic Dentistry*.

Eligibility and Cost

The exam is free of charge and is intended for and available to AACD members only. It is the responsibility of each participant to contact his or her state board for its requirements regarding acceptance of CE credits. The AACD designates this activity for 3 continuing education credits.

Testing and CE

The self-instruction exam comprises 10 multiple-choice questions. To receive course credit, AACD members must complete and submit the exam and answer at least 70% of the questions correctly. Participants will receive test results immediately after taking the examination online and can only take each exam once. The exam is scored automatically by the AACD's online testing component. The deadline for completed exams is one calendar year from the publication date of the issue in which the exam appeared. The exam is available online at www.aacd.com. A current web browser is necessary to complete the exam; no special software is needed.

Note: Although the AACD grants these CE credits, it is up to the receiving governing body to determine the amount of CE credits they will accept and grant to participants.

Verification of Participation (VOP)

VOP will be sent to AACD members via their MyAACD account upon pass completion. Log onto www.aacd.com to sign into your MyAACD account.

For members of the Academy of General Dentistry (AGD): The AACD will send the AGD proof of your credits earned on a monthly basis. To do this, AACD must have your AGD member number on file. Be sure to update your AGD member number in your AACD member profile on MyAACD.com.

All participants are responsible for sending proof of earned CE credits to their state dental board or agency for licensure purposes.

Disclaimer

AACD's self-instruction exams may not provide enough comprehensive information for participants to implement into practice. It is recommended that participants seek additional information as required. The AACD Self-Instruction Program adheres to the guidelines set forth by the American Dental Association Continuing Education Recognition Program (CERP), and the AGD Program Approval for Continuing Education (PACE).

Questions and Feedback

For questions regarding a specific course, information regarding your CE credits, or to give feedback on a CE self-instruction exam, please contact the AACD Executive Office by e-mailing meetings@aacd.com or by calling 800.543.9220 or 608.222.8583.



ADACERP
CONTINUING EDUCATION RECOGNITION PROGRAM
American Academy of Cosmetic Dentistry
is an ADA CERP Recognized Provider



ADA CERP is a service of the American Dental Association to assist dental professionals in identifying quality providers of continuing dental education. ADA CERP does not approve or endorse individual courses or instructors, nor does it imply acceptance of credit hours by boards of dentistry. AACD designates this activity for 3 continuing education credits. Concerns or complaints about a CE provider may be directed to the provider or to ADA CERP at www.ada.org/goto/cerp.

The 10 multiple-choice questions for this Continuing Education (CE) self-instruction exam are based on the article, "A 'No-Bone' Solution: Treating the Atrophic Maxilla with an Immediate Implant-Supported Fixed Prosthesis," by Mr. Stephen F. Balshi and Dr. Thomas J. Balshi. This article appears on pages 126-137.

The examination is free of charge and available to AACD members only. AACD members must log onto www.aacd.com to take the exam. Note that only Questions 1 through 5 appear in the printed and digital versions of the jCD; they are for readers' information only. The complete, official self-instruction exam is available online only—completed exams submitted any other way will not be accepted or processed. A current web browser is necessary to complete the exam; no special software is needed. The AACD is a recognized credit provider for the Academy of General Dentistry, American Dental Association, and National Association of Dental Laboratories. For any questions regarding this self-instruction exam, call the AACD at 800.543.9220 or 608.222.8583.

1. In the case presented, the reason for the severe atrophy of the maxilla was which of the following?
 - a. age-related bone loss of the maxilla
 - b. trauma to the upper jaw
 - c. extensive periodontal disease
 - d. extraction of maxillary teeth when the patient was young
2. Which of the following techniques for restoring the atrophic maxilla was utilized for the case presented?
 - a. iliac block grafting
 - b. sinus augmentation
 - c. tilted implants
 - d. Le Fort I osteotomy
3. By not using bone augmentation,
 - a. a more predictable result is achieved although there is an increase in treatment time.
 - b. the cumulative survival rate of the implants remains the same as those placed in augmented bone.
 - c. the chance of increasing the vertical dimension of occlusion is greatly reduced.
 - d. there is no concern for donor site pain, trauma, and swelling.
4. What does the "conversion prosthesis technique" discussed refer to?
 - a. Altering the existing denture from an end-on-end occlusion to a Class I occlusion.
 - b. Adapting an immediate removable denture to a screw-retained provisional prosthesis.
 - c. Modifying the existing denture by eliminating the gold onlays that were present posteriorly.
 - d. Modifying the alveolar ridge as well as the existing denture to improve the bite.
5. What is the biggest challenge facing dentists when placing implants in patients with extensive periodontal conditions or who have been edentulous for many years?
 - a. poor cumulative survival rates of implants placed in grafted maxillas
 - b. limited bone quality and quantity
 - c. medical and health issues of elderly patients
 - d. inability to graft bone due to extensive sinus pneumatization

To see and take the complete exam, log onto www.aacd.com.